



Supportive therapy in implant dentistry



To achieve long-term implant treatment success, supportive therapy must be looked upon as an integrated part of the treatment.

This is why Astra Tech has produced this manual in co-operation with Professor Tord Berglundh, who is an authority in the field. Dr. Berglundh is professor at the Department of Periodontology, The Sahlgrenska Academy at University of Gothenburg, Sweden.

Contents

Supportive therapy – a key to implant treatment success	4
Astra Tech BioManagement Complex™	
Soft and hard tissue integration	5
Peri-implant mucosa and gingiva	6
Examination of peri-implant tissues	7
Definition and diagnosis of peri-implant disease	8
Histopathology of peri-implant disease	10
Mucositis	
Peri-implantitis	
Prevalence of peri-implantitis	12
Risk factors for peri-implantitis	12
Treatment of peri-implant disease	13
Guidelines for follow-up of implant-treated patients	15
Supportive therapy – infection control	
Radiographic examination	
Clinical examination	
References	18

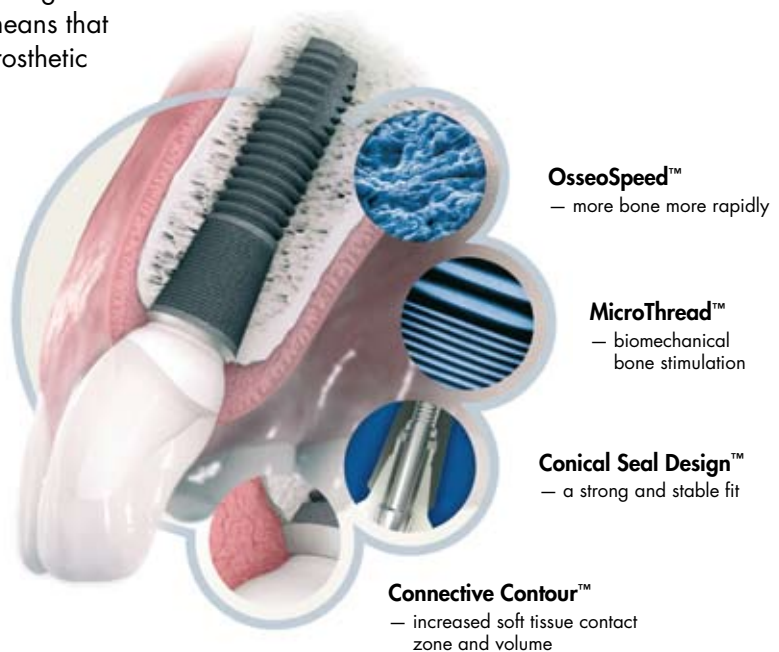
Supportive therapy – a key to **implant treatment success**

A successful outcome of implant therapy depends on a number of factors. While surgical technique and biocompatibility of implant components determine healing following implant placement, the long-term success of implant therapy requires preservation of the obtained integration between the implant and the host tissues. Microbial challenge in the oral environment may result in pathological reactions in peri-implant tissues and thereby compromising tissue integration. Thus, prevention of disease is a key factor in the aim of preserving the supporting tissues around implants. For the clinician, this means that not only are appropriate surgical and prosthetic procedures required, but also sufficient supportive therapy during maintenance, in order to achieve optimal results in implant dentistry.

This manual provides information on the examination of implant subjects during follow-up and maintenance. Diagnostic methods to guide the clinician in detecting pathology in peri-implant tissues, such as peri-implantitis, will be presented. Recommendations for prevention and treatment of such lesions will also be provided.

Astra Tech BioManagement Complex™

The design and other features of a dental implant can contribute to the establishment and preservation of tissue integration and be fundamental to the goal of supportive therapy. The Astra Tech Implant System™ exhibits a number of key features that have been shown to play important roles in these processes and are summarized as the Astra Tech BioManagement Complex™.



Soft and hard tissue integration

The integration of hard and soft tissues with implants is the result of a wound healing process. The tissue reactions that occur at recipient sites following implant placement include the formation of a blood clot that, within a few days, becomes infiltrated by vascular structures and numerous inflammatory cells to establish an early granulation tissue. The continuation of the healing process involves the substitution of the granulation tissue by organized connective tissue from which bone formation occurs that eventually results in osseointegration.

The healing events in the mucosal compartment include the formation of a barrier epithelium adjacent to the implant and, apical to this epithelium, a connective tissue that integrates with the titanium surface and thereby prevents epithelial migration. The barrier epithelium and the connective tissue/implant interface establish the specific biological width of the peri-implant mucosa (Berglundh & Lindhe 1996). The integration of hard and soft tissues with the implant device is a dynamic process that requires several weeks of healing.

- Tissue integration of a dental implant is a wound healing process.
- **Osseointegration**, the formation of bone to an implant.
- **Biological width**, the vertical dimension of the interface between the implant and the peri-implant mucosa (barrier epithelium + connective tissue).

Peri-implant mucosa and gingiva

- **Gingiva**, the soft tissue around teeth.
- **Peri-implant mucosa**, the soft tissue around implants.

The soft tissue that surrounds the transmucosal part of the implant is termed the peri-implant mucosa. The structure and dimension of this mucosa have many features in common with those of the gingiva around teeth. Besides the biological width concept that controls the thickness of the soft tissue adjacent to both teeth and implants, there are also fundamental differences between the two tissue types. Thus, the root of the tooth is covered by a root cementum from which collagen fibers run in a direction that is perpendicular to the long axis of the tooth and attach to the surrounding hard and soft tissues (*Fig. 1*). The implant has no root cementum and, hence, collagen fibers are not able to attach to the implant surface in the same way as the biological and mechanical attachment of teeth. In the peri-implant mucosa, the collagen fibers are aligned in different directions and in the tissue immediately lateral to the implant surface collagen fibers are orientated parallel to the long axis of the implant (*Fig. 2*). Nevertheless, the biological attachment formed by the barrier epithelium and the connective tissue part of the peri-implant mucosa provides an effective soft tissue seal to the oral environment.

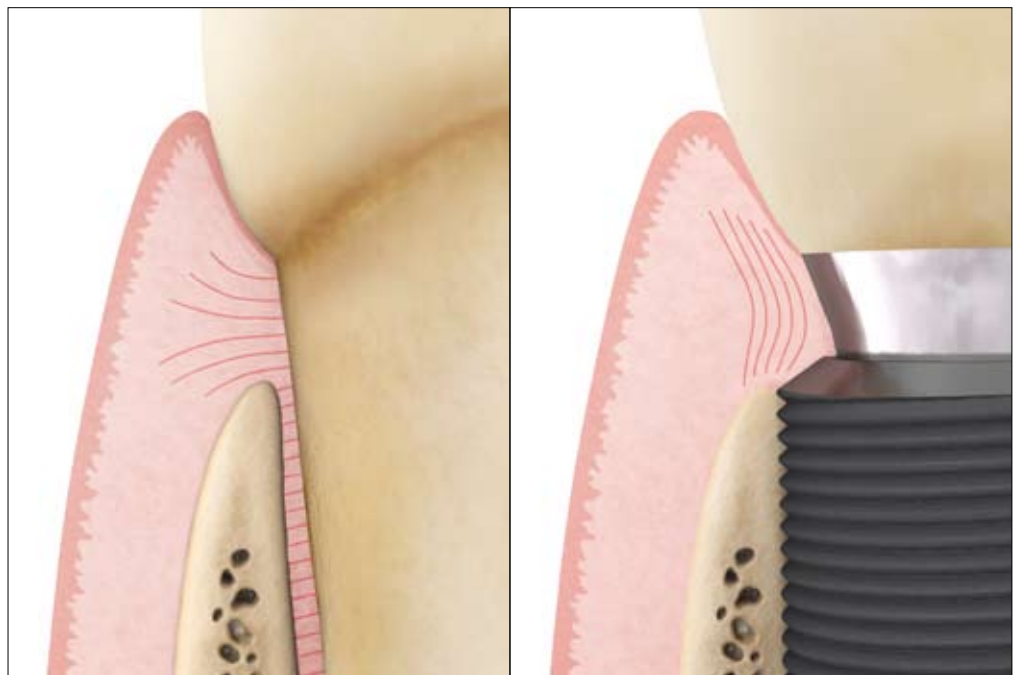


Fig. 1

Fig. 2

Examination of peri-implant tissues

The examination of peri-implant tissues is fundamental in the maintenance and follow-up of implant treated patients. The methods to be applied in the clinical examination of the tissues surrounding implants resemble those used in the examination of the periodontal tissues surrounding teeth. Thus, probing represents one of the critical assessments and includes not only the appraisal of probing pocket depth (PPD) but also the more important detection of bleeding on probing (BoP). Probing peri-implant and periodontal tissues is in most respects similar and is regarded as a predictable and reliable procedure in the effort to distinguish between healthy and diseased tissue, provided that a normal force is applied. When probing healthy tissues around implants and teeth, the probe meets resistance from the peri-implant mucosa/gingiva and the apical extension of the probe into the pocket corresponds to the vertical dimension of the junctional epithelium (*Fig. 3-4*). Probe penetration of inflamed tissues, however, is different such that the probe reaches a position apical to the epithelial extension, depending on the degree of inflammation (Schou et al. 2002).

- Peri-implant soft tissue health is critical for the long-term survival and esthetic stability of dental implants.
- **Bleeding on Probing (BoP)** and **Probing Pocket Depth (PPD)** are important examination procedures in the effort to distinguish between healthy and diseased tissues.

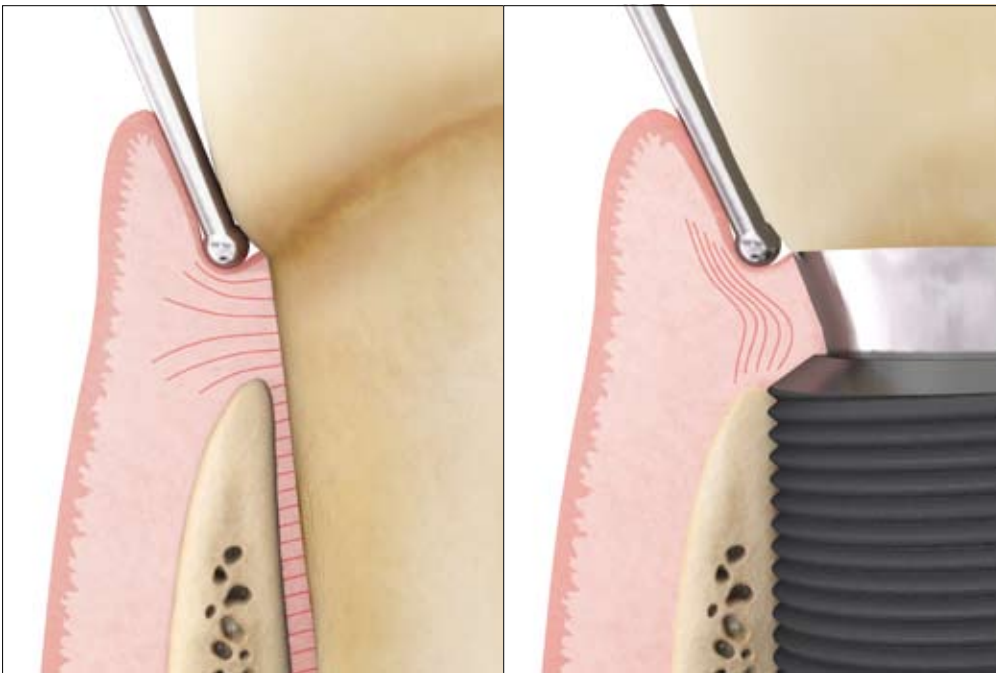


Fig. 3

Fig. 4

Definition and diagnosis of peri-implant disease

Periodontal diseases around teeth are classified as gingivitis and periodontitis. Gingivitis refers to gingival inflammation with no signs of loss of supporting tissues, while periodontitis in addition to gingival inflammation is characterized by loss of attachment and bone. Inflammatory lesions that develop in peri-implant tissues are collectively termed peri-implant disease. In accordance with the classification of periodontal disease around teeth, peri-implant disease includes two entities: peri-implant mucositis, which corresponds to gingivitis and peri-implantitis, which corresponds to periodontitis. Thus, peri-implant mucositis is a condition that describes inflammation in the mucosa, while peri-implantitis in addition also affects the supporting bone (Lindhe & Meyle 2008).

The detection of inflammation in the peri-implant mucosa requires probing to identify bleeding and/or suppuration. While the probing pocket depth (PPD) may vary around implants, such assessments are secondary to bleeding on probing (BoP). Sites with PPD \geq 6 mm, however, may indicate pathology and should thus be examined meticulously (*Fig 5*). For the appraisal of peri-implantitis, the detection of marginal bone loss in radiographs is also needed. In this context, it is important to distinguish between the bone remodeling that occurs early after implant installation and the loss of supporting bone that may be detected around implants during function. Thus, for appropriate evaluation of bone level changes around implants a reference radiograph, obtained directly after the delivery of the prosthesis, is required.

Disease site	Inflammation but no loss of supporting tissues	Inflammation + loss of supporting tissues
Periodontal	<i>Gingivitis</i>	<i>Periodontitis</i>
Peri-implant	<i>Peri-implant mucositis</i>	<i>Peri-implantitis</i>

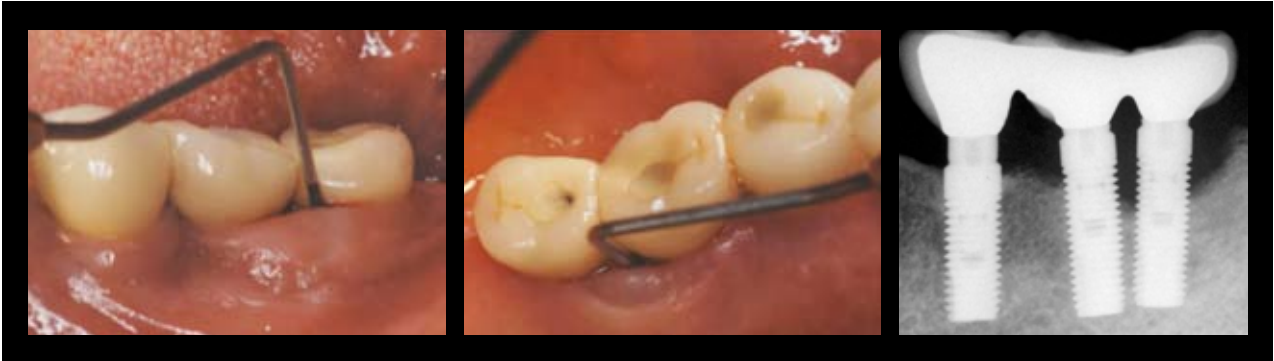

Fig 5

Histopathology of peri-implant disease

Mucositis

Findings from animal experiments and analyses of human biopsy material have revealed that the inflammatory lesions in peri-implant mucositis and gingivitis are similar. The development of inflammatory lesions in the connective tissue in the marginal portion of the gingiva or peri-implant mucosa as a response to microbial challenge follows the same pattern and the composition of inflammatory cells in the two lesions is also similar (Fig. 6–7). Gingivitis and mucositis are reversible conditions since the inflammatory lesion can be completely resolved after the institution of appropriate infection control measures.

- Peri-implant mucositis and gingivitis have many features in common.
- Both conditions are reversible.

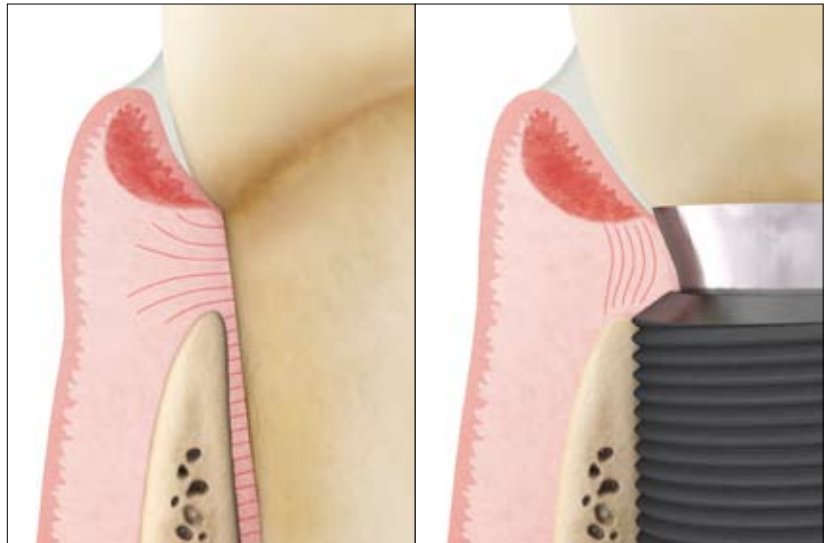


Fig 6

Fig 7

Peri-implantitis

Peri-implantitis lesions, in contrast to mucositis lesions, exhibit characteristics that are considerably different from their periodontal counterparts (Fig. 8–9). The inflammatory lesion in periodontitis around teeth is confined to the sub-epithelial connective tissue compartment of the gingiva and is separated from the alveolar bone by a 1mm-wide zone of dense connective tissue. Furthermore, the pocket area is lined by a pocket epithelium, which in its most apical portion is in contact with the root surface and thereby effectively walls off the biofilm of bacteria in the pocket.

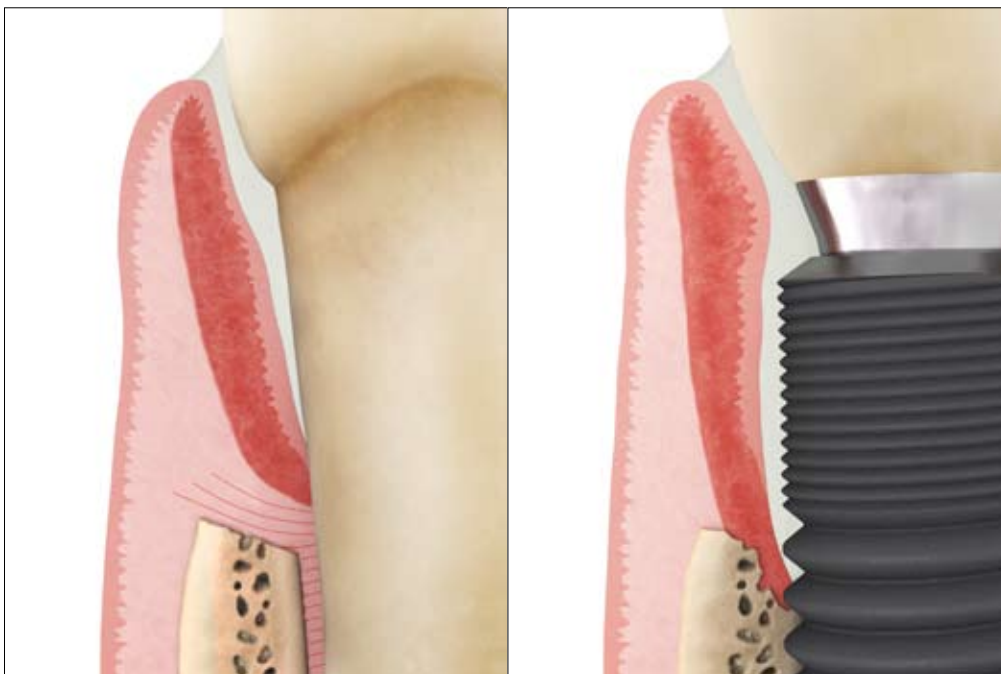

Fig 8

Fig 9

The peri-implantitis lesion also presents with a pocket compartment that contains bacteria. In contrast to the pocket epithelium in periodontitis, however, the corresponding epithelium of the peri-implantitis lesion does not cover the entire extension of the pocket. As a consequence, the apical third of the inflamed tissue in the pocket is uncovered and in direct contact with the biofilm. Another difference in relation to periodontitis is the extension of the inflammatory lesion in peri-implantitis. While the lesion in periodontitis is separated from the crestal bone by a zone of connective tissue, the lesion in peri-implantitis extends to a position close to the bone surface. An understanding of these differences between periodontitis and peri-implantitis is important in the selection of strategies for treatment of the disease.

- Peri-implantitis and periodontitis lesions exhibit several histopathological differences. While the lesion in periodontitis is separated from the crestal bone by a zone of connective tissue, the lesion in peri-implantitis extends to a position close to the bone surface.
- The differences between peri-implantitis and periodontitis must be considered in the selection of strategies for treatment of the disease.

- Different studies present figures ranging from 28 to 56% of subjects with peri-implantitis at one or more implants.
- 10 -15% of implant-treated patients present significant disease with pronounced bone loss at several implants.

Prevalence of peri-implantitis

Few studies have reported on the prevalence of peri-implant diseases (Zitzmann & Berglundh 2008). In the available studies, the proportion of subjects who exhibited peri-implantitis around one or more implants varied from 28 to 56 %. The extent and severity of the disease, however, vary among subjects, with about 10-15 % of subjects appearing to exhibit significant peri-implantitis with pronounced bone loss at several implants. While most of the current information on the prevalence of peri-implantitis has been obtained from subjects who were treated with one implant system, it is imperative to realize that this disease is generic and may occur around all types of implants.

Risk factors for peri-implantitis

Subjects with a high susceptibility to periodontitis are considered to be at a higher risk for peri-implantitis (Heitz-Mayfield 2008). Although all implant patients require sufficient follow-up and supportive therapy during maintenance, subjects susceptible to

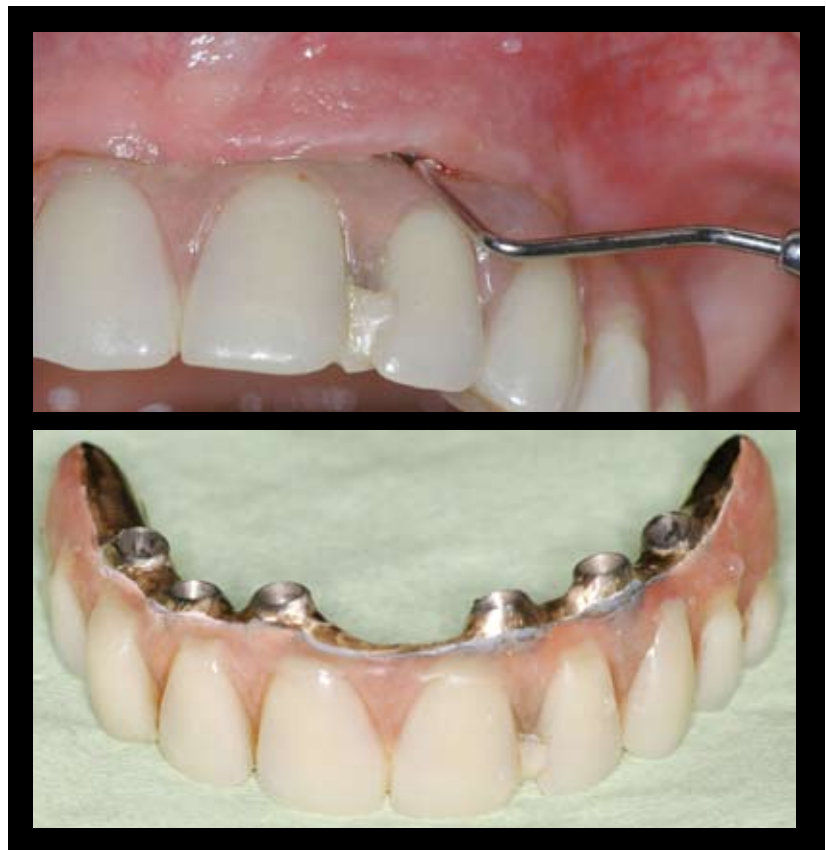

Fig 10

periodontitis should be provided with comprehensive infection control during follow-up in order to prevent peri-implant disease. Peri-implantitis, as periodontitis around teeth, is more frequent among smokers than non-smokers.

As reported in clinical and experimental studies, implant surface characteristics are an additional risk factor for peri-implantitis. Not only surface roughness but also surface composition appears to influence the onset and progression of peri-implantitis.

The design of the implant-supported prosthesis may be another risk factor for peri-implant disease. Access for infection control procedures performed by the patient and the dentist and/or dental hygienist must be provided in order to prevent inflammation in the peri-implant tissues (*Fig. 10*).

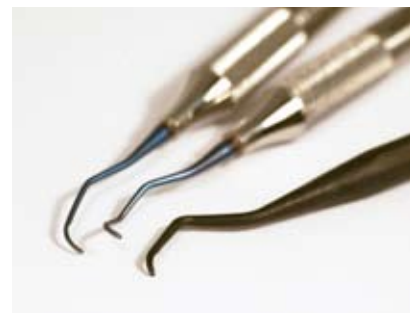Treatment of peri-implant disease

Peri-implant mucositis and peri-implantitis are infectious diseases and, consequently, treatment procedures must be aimed at eliminating the infection to resolve inflammatory lesions in peri-implant tissues. Thus, the goal in the treatment of these conditions is to achieve pocket closure and absence of bleeding on probing. The treatment should also result in prevention of the loss of supporting tissues, which is accomplished by adequate supportive therapy. Fundamental to these goals is infection control.

All subjects who present any signs of peri-implant disease should be thoroughly informed about the disorder and instructed on how to carry out self-performed infection control. Whether the disease is mucositis or peri-implantitis, the initial phase of therapy must always include infection control procedures. Professional infection control procedures include the removal of hard and soft bacterial deposits on implant and suprastructure components with scalars. The instruments to be used should not damage the implant components or the surrounding tissues. In this context, it is imperative to point out that deep, “blind” instrumentation, such as “subgingival debridement” that normally is performed around teeth, is not recommended in non-surgical treatment of peri-implant disease. The reason for this difference in strategy is related to the geometry of the implant device with its threaded part and other obstacles to access. The risk of causing injury to the inflamed tissues when performing blind instrumentation must also be emphasized.

Risk factors to be considered with respect to the onset and progression of peri-implantitis:

- History of severe periodontitis
- Smoking
- Implant surface properties
- Design of prosthesis – accessibility for infection control



The treatment of peri-implantitis will often but not always require surgery. The purpose of surgical therapy is to provide access for debridement and decontamination of the implant surface. After flap elevation, meticulous mechanical cleansing of the exposed implant therapy is performed (*Fig. 11*). Presently, there is no documentation supporting any particular antiseptic agent to be used during cleaning being more effective than others. While peri-implantitis lesions are associated with bone loss resulting in defects of varying size and morphology, surgical treatment procedures also include strategies for the management of the hard tissue component. The common problem of lack of bone support on buccal and/or lingual aspects of bone defects associated with peri-implantitis requires resective procedures in which bone recontouring is performed to outline the bone morphology in order to facilitate soft tissue adaptation and pocket elimination (*Fig. 12*). In other situations, when the defect morphology allows reconstructive procedures, the use of e.g. bone grafts and guided bone regeneration may be considered, provided that appropriate anti-infective measures are carried out to achieve resolution of the peri-implantitis lesion.



Fig 11

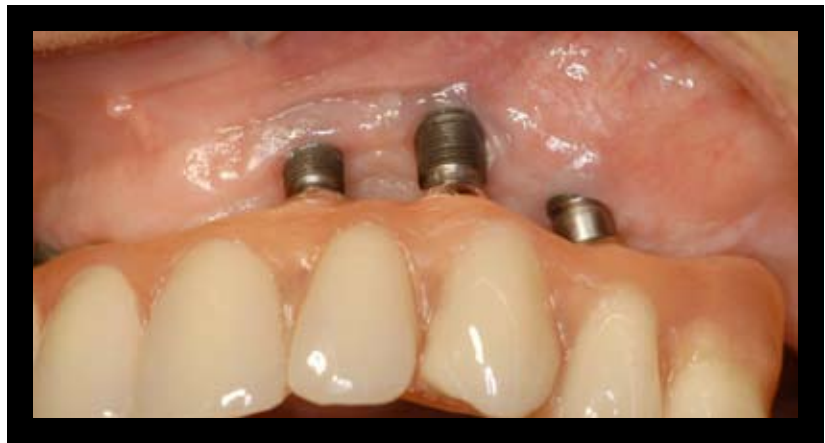

Fig 12

- The goal in the treatment of peri-implant disease is to achieve pocket closure and absence of bleeding on probing. The treatment should also result in prevention of loss of supporting tissues, which is accomplished by adequate supportive therapy.
- Fundamental to these goals is self-performed and professional infection control.
- Professional infection control procedures include the removal of hard and soft bacterial deposits on implant and suprastructure components.
- The objective of surgical therapy in treatment of peri-implantitis is to provide access for the debridement and decontamination of the implant surface.

Guidelines for follow-up of implant-treated patients

Supportive therapy – infection control

Following the completion of the surgical and prosthetic procedures in implant therapy, it is imperative to inform the patient about how to carry out self-performed infection control procedures. Thus, depending on the design of the prosthetic reconstruction, different types of toothbrushes and/or floss should be used to properly clean the implant and adjacent parts of the prosthesis twice a day (*Fig. 13*). The design of the prosthetic reconstruction must allow access for self-performed and professional infection control.

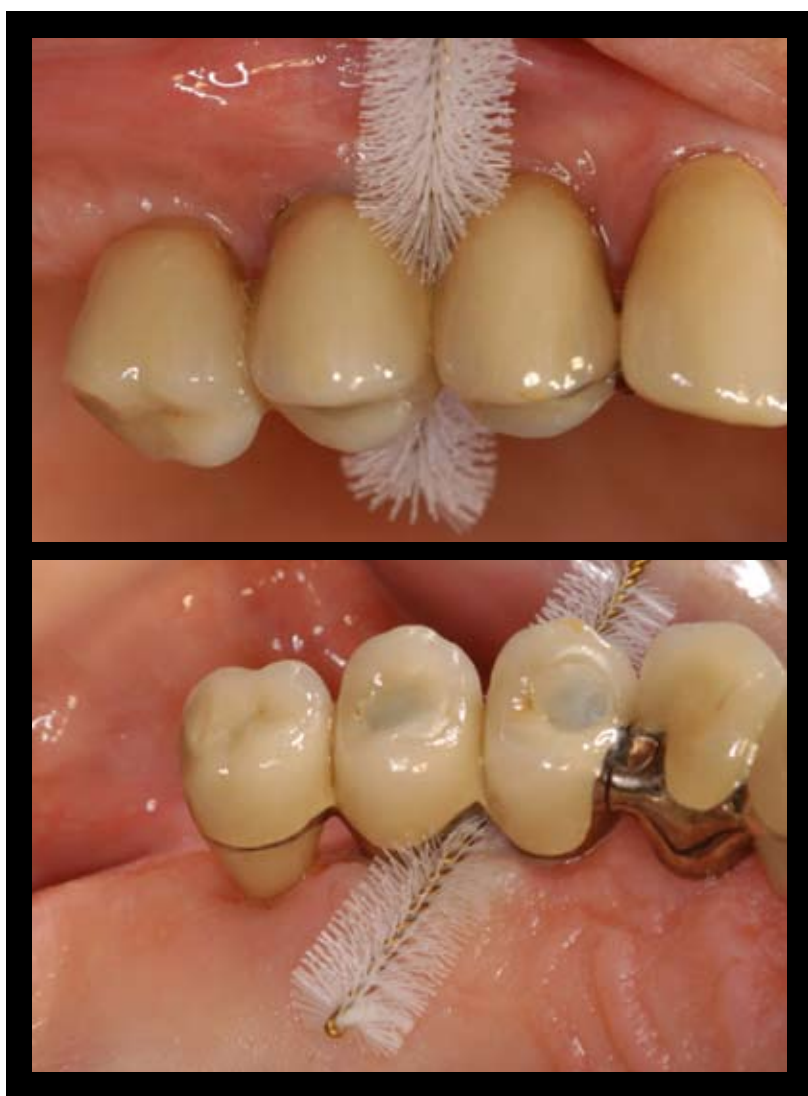

Fig 13

Radiographic examination

Radiographic examination of the implant sites should be carried out at the time of the connection of the prosthesis and at the one-year follow-up. Possible marginal bone level changes documented during the first year in function of an implant may be associated with the bone remodeling after implant installation. The information thereby obtained forms a baseline for subsequent bone level evaluations.

(Fig. 14).

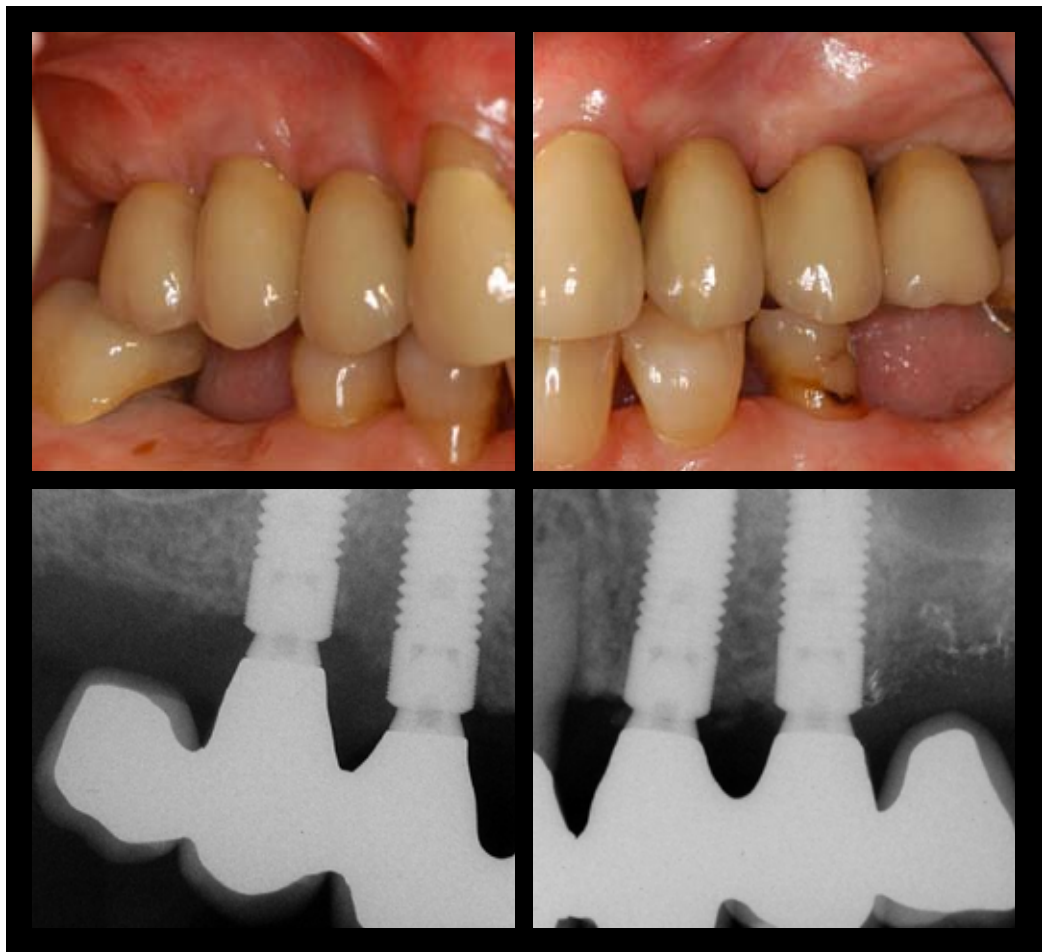


Fig 14

Clinical examination

Clinical examinations should be performed at all annual follow-up visits. Besides checking the function of the prosthesis, this examination should include evaluations of BoP, PPD and plaque. If the probing indicates peri-implant disease (BoP positive) and PPD ≥ 6 mm, these findings call for a radiographic examination to reveal possible bone loss in relation to baseline radiographs. In the absence of clinical findings of pathology in peri-implant tissues, radiographic examination should be avoided. Following the diagnosis of either mucositis or peri-implantitis, however, appropriate infection control measures should be initiated as described above.

The recall system for follow-up of implant-treated patients should be designed in accordance with evaluation of risk factors for peri-implant disease. Thus, subjects with a history of severe periodontitis require a recall program with examinations and supportive therapy carried out every 2 - 6 months after the delivery of the prosthesis.

- Radiographic documentation at prosthesis delivery and at one-year follow-up forms the baseline for bone level evaluations.
- Self-performed infection control by the patient, with appropriate tooth-brushes and/or floss, should be carried out twice a day.
- The recall system for follow-up of implant-treated patients should be designed in accordance with risk factors for peri-implant disease.
- Clinical examinations should be performed and supportive therapy should be provided at least annually.
- Findings of BoP and PPD > 6 mm call for radiographic examination.
- If no clinical signs of pathology are detected, radiographic examination should be avoided.

References

Berglundh, T. & Lindhe, J. (1996). Dimensions of the periimplant mucosa. Biological width revisited. *Journal of Clinical Periodontology*, 23, 971-973.

Schou S, Holmstrup P, Stoltze K, Hjørting-Hansen E, Fiehn NE & Skovgaard LT. (2002) Probing around implants and teeth with healthy or inflamed peri-implant mucosa/gingiva. A histologic comparison in cynomolgus monkeys. *Clinical Oral Implants Research*, 13:113-26.

Lindhe J & Meyle J. (2008) Peri-implant diseases: Consensus Report of the Sixth European Workshop on Periodontology. Group D of European Workshop on Periodontology. *Journal of Clinical Periodontology*, (Suppl), 35, 282-285.

Zitzmann, NU & Berglundh, T. (2008) Definition and prevalence of peri-implant diseases. Proceedings from the 6th European Workshop on Periodontology. *Journal of Clinical Periodontology*, (Suppl), 35, 286-291.

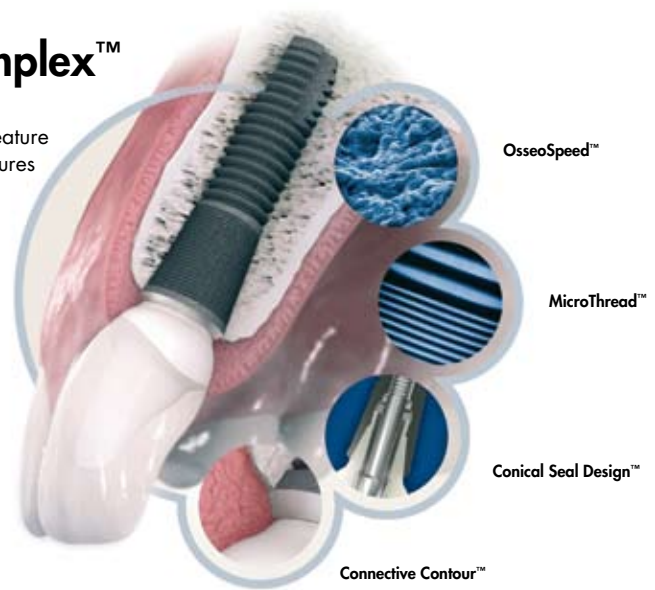Heitz-Mayfield LJ. (2008) Peri-implant diseases: diagnosis and risk indicators. Proceedings from the 6th European Workshop on Periodontology. *Journal of Clinical Periodontology*, (Suppl), 35, 292-304.



Astra Tech BioManagement Complex™

A successful implant system cannot be determined by one single feature alone. Just as in nature, there must be several interdependent features working together. The following combination of key features is unique to the Astra Tech Implant System™:

- **OsseoSpeed™** – more bone more rapidly
- **MicroThread™** – biomechanical bone stimulation
- **Conical Seal Design™** – a strong and stable fit
- **Connective Contour™** – increased soft tissue contact zone and volume



Australia

Astra Tech Pty Ltd.
Suite 1, 53 Grandview St, Pymble NSW 2073
☎ +61 2 9488 3500. 📠 +61 2 9440 0744
www.astratechdental.com.au

Austria

Astra Tech GesmbH
Schloßhofer Straße 4/4/19, AT-1210 Wien
☎ +43-(0)1-2146150. 📠 +43-(0)1-2146167
www.astratechdental.at

Benelux

Astra Tech Benelux B.V.
Signaalrood 55, NL-2718 SG Zoetermeer
☎ +31 79 360 1955/+32 3 232 81 50
📠 +31 79 362 3748/+32 3 213 30 66
www.astratechdental.nl

Canada

Astra Tech Inc.
2425 Matheson Blvd East, 8th Floor
Mississauga, ON L4W 5K4
☎ +1 905 361 2844
www.astratechdental.com

Denmark

Astra Tech A/S
Roskildevej 163, 1. th. 2620 Albertslund
☎ +45 43 71 33 77. 📠 +45 43 71 78 65
www.astratechdental.dk

Finland

Astra Tech Oy
PL 96, FI-02231 Espoo
☎ +358 9 8676 1626. 📠 +358 9 804 4128
www.astratechdental.fi

France

Astra Tech France
7, rue Eugène et Armand Peugeot, TSA 90002
FR-92563 Rueil Malmaison Cedex
☎ +33 1 41 39 02 40. 📠 +33 1 41 39 02 44
www.astratechdental.fr

Germany

Astra Tech GmbH
An der kleinen Seite 8, DE-65604 Elz
☎ +49 6431 9869 0. 📠 +49 6431 9869 500
www.astratechdental.de

Italy

Astra Tech S.p.A.
Via Cristoni, 86, IT-40033 Casalecchio di Reno (BO)
☎ +39 051 29 87 511. 📠 +39 051 29 87 580
www.astratechdental.it

Japan

Astra Tech K.K.
1-7-16 Sendagaya, Shibuya-ku, Tokyo 151-0051
☎ +81 3 5775 0515. 📠 +81 3 5775 0571
www.astratech.jp

Norway

Astra Tech AS
Postboks 160, NO-1471 Lørenskog
☎ +47 67 92 05 50. 📠 +47 67 92 05 60
www.astratechdental.no

Poland

Astra Tech Sp.z o.o.
ul. Orężna 58 02-937 Warszawa
☎ +48 22 853 67 06. 📠 +48 22 853 67 10
www.astratechdental.com

Spain

Astra Tech S.A.
Calle Ciencias nº 73 derecha. Nave 9,
Polígono Industrial Pedrosa,
ES-08908 L'Hospitalet de Llobregat
☎ Servicio al cliente: +34.902.101.558
☎ +34.932.643.560. 📠 +34.933.363.231
www.astratechdental.es

Sweden

Astra Tech AB
Aminogatan 1, P.O. Box 14, SE-431 21 Mölndal
☎ +46 31 776 30 00. 📠 +46 31 776 30 17
www.astratechdental.se

Switzerland

Astra Tech SA
Avenue de Sévelin 18, P.O. Box 54
CH-1000 Lausanne 20
☎ +41 21 620 02 30. 📠 +41 21 620 02 31
www.astratechdental.ch

United Kingdom

Astra Tech Ltd.
Brunel Way, Stonehouse, Glos GL10 3SX
☎ +44 1453 791763. 📠 +44 1453 791001
www.astratechdental.co.uk

USA

Astra Tech Inc.
590 Lincoln Street, Waltham, MA 02451
☎ +1-800-531-3481. 📠 +1-781-890-6808
www.astratechdental.com

Other Markets

Astra Tech AB, Export Department
Aminogatan 1, P.O. Box 14,
SE-431 21 Mölndal, Sweden
☎ +46 31 776 30 00. 📠 +46 31 776 30 23
www.astratechdental.com



A company in the
AstraZeneca Group